



Prevalence and Histopathological Effects of Fascioliasis in Cattle Slaughtered in Ikot Eneobong Abattoir, Calabar, Nigeria

**Usang Anok Ukam¹, Imalele Edema Enogiomwan^{1*},
Effanga Emmanuel Offiong¹ and Osondu-Anyanwu Chinyere²**

¹Department of Zoology and Environmental Biology, Faculty of Biological Sciences, University of Calabar, Calabar, Cross River State, Nigeria.

²Department of Science Laboratory and Technology, Faculty of Biological Sciences, University of Calabar, Calabar, Cross River State, Nigeria.

Authors' contributions

This work was carried out in collaboration among all authors. Authors UAU and IEE designed the study and drafted the manuscript. Authors UAU and EEO managed the literature searches. Authors UAU and EEO were involved in data acquisition. Authors OAC, EEO and IEE performed the statistical analysis. Author OAC rendered technical support. Funding was obtained from all authors. Author UAU drafted the manuscript. All authors read and approved the final manuscript.

Article Information

DOI: 10.9734/MRJI/2020/v30i530218

Editor(s):

(1) Prof. Essam Hussein Abdel-Shakour, Al-Azhar University, Egypt.

Reviewers:

(1) Vinay Kumar Singh, Deen Dayal Upadhyaya Gorakhpur University, India.

(2) Luciano Silva Sena, Brazil.

(3) Dora Ana Davies, Universidad Nacional de Salta, República Argentina.

Complete Peer review History: <http://www.sdiarticle4.com/review-history/57640>

Original Research Article

Received 26 March 2020

Accepted 04 June 2020

Published 16 June 2020

ABSTRACT

Aims: Studies were carried out to determine the prevalence, intensity, economic loss and histopathological effects of fascioliasis in cattle slaughtered in Ikot Eneobong abattoir, Calabar, Cross River State, Nigeria.

Study Design: The study involved Post-Mortem examination of 384 liver samples from slaughtered cattle.

Place and Duration of Study: Department of Zoology and Environmental Biology, University of Calabar, Calabar, Cross River State, Nigeria, between April – July, 2015.

Methodology: A total of 384 liver samples were examined for individuals of *Fasciola gigantica* by making length-wise incision on the ventral side of the liver. Recovered flukes were counted and

*Corresponding author: E-mail: edemaeddy@gmail.com;

grouped into different levels of intensity. Infected livers recovered were subjected to histopathological analysis using haematoxylin and eosin (H&E) staining technique. The economic loss due to the infection was determined based on the current market price per kg weight of cattle liver.

Results: Out of the 384 livers examined, 64 (16.67%) were found positive for fascioliasis. The month of July had the highest prevalence of infected livers (25.64%) while the month of April which had the lowest prevalence of infected livers (11.02%) ($P=.05$). Out of the 64 diseased livers, 58 (90.6%) had light worm load, 5 (7.8%) had moderate worm load and 1 (1.6%) had heavy worm load with numbers significantly higher in July compared with April, May and June ($P=.05$). In the four months study period, 320kg of livers from 64 cattle valued at ₦256,000 were lost due to infection. Histological examination of infected livers revealed necrosis, fibrosis, degenerated hepatocytes, proliferation of the bile ductules and marked infiltration of mononuclear inflammatory cells.

Conclusion: This study has established the prevalence, economic loss and histopathological consequences of fascioliasis in Ikot Eneobong abattoir. As such it is important that the routine examination of slaughtered ruminants be conducted prior to their presentation for public consumption.

Keywords: Fascioliasis; economic loss; histopathology; liver; cattle.

1. INTRODUCTION

Fascioliasis is an important parasitic food borne disease responsible for significant public health problems and major economic losses to the livestock industry [1]. The two main species responsible for this infection are *Fasciola hepatica* and *Fasciola gigantica* [1]. Millions of carcasses and livers are lost due to damage caused by *Fasciola* infection in cattle [2]. The direct economic impact of fascioliasis infection is increased condemnation of liver meat, but the far more damaging effects are reduced growth in infected animals, lower calf birth weight and decreased animal productivity [3].

Transmission of fascioliasis is dependent upon and aggravated by some factors such as: the absence of a substantial reservoir of water, presence of a potential definitive host and the presence of the lymnaeid snail intermediate host [4]. Furthermore transmission of fascioliasis has been said to occur during the dry season when livestock feed in restricted areas and drink off water sources like dams, holes and snail infested areas [4].

The damage caused by *Fasciola* to the host includes the destruction of liver tissues, reduction of body weight gain in infected cattle, reduction in milk production, composition and quality [5].

Several studies have reported the prevalence of fascioliasis in Africa [6,7,1,8,9] and in other parts of the world [10,11]. This shows that the disease continues to pose a serious problem to livestock farming.

The liver is one of the vital organs of the body, which is susceptible to various parasites and disease conditions such as fascioliasis, which affect the health status of the animal. Parasites and diseases damage the livers of cattle and make the liver unsuitable for human consumption. This leads to serious economic loss as infected livers are condemned at meat inspection [12,13]. The present study is therefore aimed at determining the prevalence of fascioliasis and the histopathology of infected liver in slaughtered cattle from Ikot Eneobong abattoir. The economic loss due to fascioliasis infection was also taken into consideration.

2. METHODOLOGY

2.1 Description of Study Area

The study area was Ikot Eneobong in Calabar, Cross River State. Calabar is located between 5°2'40"N and 8°21'20" E. Calabar is the capital of Cross River State and divided into Calabar Municipal and Calabar South Local Government Areas. It has an area of 406 Km² and a population of 371,022 [14]. It is located in the rain forest belt of Nigeria and has a tropical climate.

Ikot Eneobong is one of the peri-urban areas of Calabar Municipality. This area is located about 7-8km away from Calabar Municipality. This community has features of both urban and rural settings. The residents in this area are mostly civil servants, traders, farmers and artisans. The community has an abattoir called Ikot Eneobong Abattoir which is the largest in Calabar, where large numbers of cattle are slaughtered daily. Cattle slaughtered in Ikot Eneobong Abattoir are

imported from Northern Nigeria, particularly, Borno State and are mainly the Red Bororo, White Fulani and cross breeds.

2.2 Study Design

The study was conducted between April – July, 2015. The abattoir was visited once a week for 16 weeks. A total of 384 cattle were examined. The inspection of the liver was made possible through the cooperation of the veterinary staff on duty at the abattoir. The sex of slaughtered cattle was observed and recorded for each sample throughout the study. Only male cattle were available during the study. Females are usually kept for reproductive purposes. The age of slaughtered cattle ranged from 36 – 42 months.

2.3 Parasitological Examination

For each slaughtered Cattle, the liver was thoroughly examined along the side of the bile duct for *Fasciola* specimens. The infected liver was placed on a clean board and dissected in-situ using a well sharpened knife, the bile duct was opened and all the flukes found were removed, placed in a petri dish containing 10% formalin as preservative and then were examined. The total number of flukes seen was recorded [15]. Tissue samples for both infected and non-infected liver were collected for proper histopathological procedures.

Individuals found in each infected liver were counted and categorized into light (0-20 worms), moderate (21-49 worms) and heavy (≥ 50 worms) worm burden [16].

2.4 Histological Preparation of Liver Tissue Samples

Infected livers of cattle were fixed in Bouin fluid for 24 hrs and then washed with tap water for 12 hrs. Fixed tissues were dehydrated in ascending grades of ethanol (70%, 95% and absolute concentration). Dehydrated tissues were cleared in xylene, infiltrated in liquid paraffin wax at 56°C and embedded in clean wax to block. Blocked tissues were mounted in wood frames and cut into 5 μ thick sections using rotary microtome. Cut sections were flattened on water bath at 40°C and picked with clean albumenized slides. Sections were then dewaxed in descending grades of ethanol (absolute concentration, 95% and 70%). Dewaxed sections were then stained with haematoxylin and counter stained with eosin (H & E), dehydrated in ethanol, cleared in xylene and mounted with cover slip for examination [17].

2.5 Determination of Economic Loss from Liver Condemnation Due to Fascioliasis

The total monthly economic loss incurred due to liver condemnation at the abattoir was computed by multiplying the average weight of infected livers with the mean price of 1 kg liver [18].

The direct annual loss from condemned livers was assessed by considering the overall prevalence rate of the disease, the total annual slaughtered animals in the abattoir and the retail price of an average liver [19].

$$ALC = MCS \times MLC \times P$$

Where:

ALC = Direct Annual Loss; MCS = Mean annual cattle slaughtered at the abattoir; MLC = Mean cost of one liver; P = Prevalence rate of the disease in the study abattoir.

2.6 Data Analysis

The prevalence was expressed as percentage of the total animals sampled. The *Chi-square* test was used to test for significant differences in prevalence across the months. Intensity of infection was analyzed using ANOVA and P-values < 0.05 were considered significant. All analysis was done using SPSS, version 22.

3. RESULTS

3.1 Determination of Prevalence of Fascioliasis

A total of 64 out of the 384 male cattle examined were infected with individuals of *Fasciola gigantica*, giving the overall prevalence rate of 16.67%. According to months, April, May, June and July recorded prevalence of 11.02%, 17.04%, 15.96% and 25.64%, respectively. The prevalence varied significantly across the months ($P = 0.000$) (Table 1).

3.2 Intensity of Infection

Generally, of the 64 cases of cattle with infected livers, 58 (90.6%) had light worm burden (0-20 worms), 5 (7.8%) had moderate worm burden (21-49 worms) and 1 (1.6%) had heavy worm burden (≥ 50 worms).

The highest rate of infected liver with light infection was recorded in the month of July with 20 infections (34.48%) and the lowest rate of infection with light infection was recorded in the month of April with an intensity of 11 (18.96%). Light infection varied significantly across the months ($P = .05$) (Table 2).

The highest rate of infected liver with moderate infection was recorded in the months of April and June, with an intensity of 4 (80%), while the lowest rate of 1 (20%) was recorded in the month of May. However, this difference is not significant ($P = .700$) across the months (Table 2).

3.3 Economic Loss from Liver Condemnation due to Fascioliasis in Cattle Slaughtered in Ikot Eneobong Abattoir

In the four months studied, 320 kg condemnable weight of livers from 64 cattle valued at ₦ 256,000 (1,280 US \$) was lost due to fascioliasis. The study showed that the month of July had the highest monetary loss of ₦ 80,000 from *Fasciola hepatica* infection due to liver condemnation

while the month of April had the lowest amount lost (₦ 56,000) (Table 3).

On average 3072 male cattle is slaughtered annually, while the mean retail price of bovine liver was ₦ 800 and prevalence of fascioliasis in Ikot Eneobong abattoir was estimated to be 16.67%. Therefore, the estimated annual loss from liver condemnation was ₦ 40,968,192.

$$ALC = MCS \times MLC \times P = 3072 \times 800 \times 16.67 = 40,968,192$$

3.4 Liver Inspection

Sixty four (64) liver samples were found to be infected with *Fasciola gigantica* during meat inspection in the study (Fig. 1a). An uninfected liver is shown in Fig. 1b. The *F. gigantica* infected livers showed numerous varying size nodules distributed in no particular pattern with reddish brown patches sandwich between large black areas or sections. This is against normal liver with uniformly brown coloured distribution. This appearance was observed in all infected cattle. The exceptions were livers with low worm burden (1-3 flukes per liver).

Table 1. Prevalence of fascioliasis studied from liver samples of cattle slaughtered in Ikot Eneobong abattoir

Months	Number of cattle examined	Number of cattle infected	Percentage (%)
April	127	14	11.02*
May	85	15	17.64*
June	94	15	15.96*
July	78	20	25.64*
Total	384	64	16.67

*indicates $P = .05$ using chi-square statistic

Table 2. Intensity of fascioliasis in cattle slaughtered in Ikot Eneobong abattoir in relation to the total number of worms recovered per liver

Worm burden	Months			
	April (%)	May (%)	June (%)	July (%)
Light infection (n=58)	11 (18.96)*	14 (24.14)**	13 (22.41)**	20 (34.48)
Moderate infection (n=5)	2 (40.00)**	1 (20.00)	2 (40.00)	-
Heavy infection (n=1)	1 (100)	-	-	-

*indicates light infections varied significantly across the months at $P = .05$. **indicates $P = .700$ using chi-square statistic

Table 3. Total estimated loss from fascioliasis in cattle slaughtered at Ikot Eneobong abattoir due to condemned liver

Study months	Number of cattle examined	No. of infected livers (N = 384)	Total weight of infected liver (kg)	Estimated loss at ₦ 800 per kg
April	127	14	70	₦ 56,000
May	85	15	75	₦ 60,000
June	94	15	75	₦ 60,000
July	78	20	100	₦ 80,000
Total	384	64	320	₦ 256,000

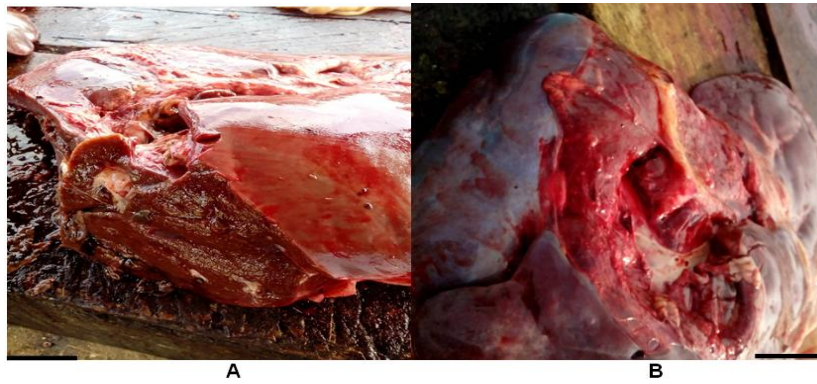


Fig. 1. A. Photograph of an infected cattle liver (40×) B. An uninfected cattle liver (40×)

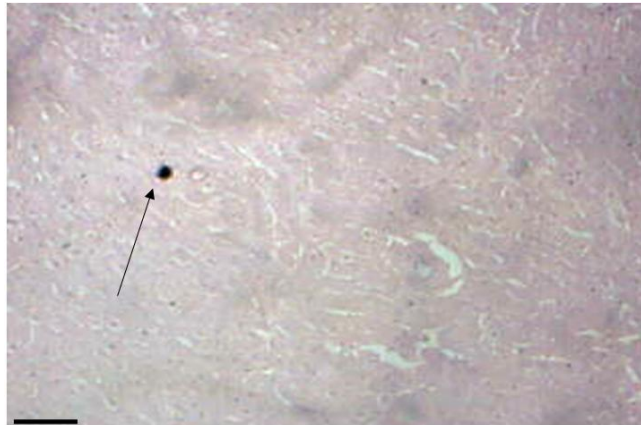


Fig. 2. Photomicrograph of section of cattle liver showing a normal liver with central vein and radiating cords of hepatocytes (black arrow), Mag: ×10 Haematoxylin and Eosin stain (H & E)

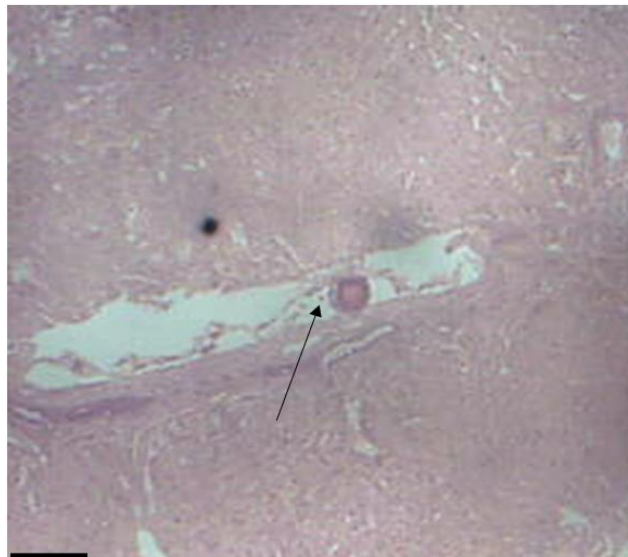

Fig. 3. Photomicrograph of section of cattle liver with fascioliasis around the central canal leading to a congestive central vein (black arrow), Mag: ×10 Stain (H & E)

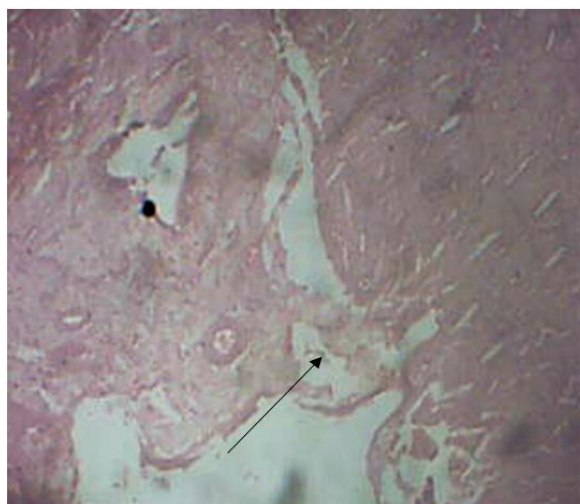


Fig. 4. Photomicrograph of section of cattle liver showing extensive fibrous connective tissue proliferation in the portal area with infiltration of mononuclear inflammatory cells (black arrow), Mag: $\times 10$ Stain (H & E)

3.5 Histopathological Effects of Fascioliasis on the Infected Cattle Livers

Examination of infected livers revealed the following histopathological consequences. Fig. 2 shows a normal liver structure with the central vein and radiating cords of hepatocytes. Fig. 3 shows an abnormal liver with immature fluke in dilated and thickened bile duct. Fig. 4 shows liver with proliferation of bile ductules, expansion of portal tracts by marked infiltration of mononuclear inflammatory cells.

4. DISCUSSION

Out of the 384 cattle examined, 64 (16.67%) were infected. This quantity is low in comparison with a similar study by Abraham and Jude [20], in Calabar abattoirs, which recorded a prevalence of 44.8% for bovine fascioliasis in slaughtered cattle and Ayelign and Alemneh [21] who reported a prevalence of 47.10% of bovine fascioliasis in Ethiopia. However, the prevalence of 16.67% recorded in this study is higher than the 10.51% reported for Onitsha abattoir [22], 7.35% for Ikom abattoir [23] and 5.1% for Wudil Local Government Area abattoir as reported by Yahaya and Tyav [24] all in Nigeria. The result of this study is slightly different from the report of Usip et al. [16] who reported 13.62% prevalence of *Fasciola* infection in cattle slaughtered in Eket abattoir, Akwa Ibom State, Nigeria. The ecological condition of an area can also be seen

as a determining factor for the prevalence of *Fasciola* infection. This can be seen in the study conducted by Njoku-Tony [7] in selected abattoirs in Imo State, Nigeria. It was reported that the observed variation in the infection from one abattoir to another was due to the varying climatic and ecological conditions of the area where the animals grazed before getting to the abattoir. These observations were also made by Odigie and Odigie [1] and Ngele and Ibe [25].

The prevalence varied significantly across the months ($P = 0.000$) with infection higher in July. Jaja et al. [26] stated that the high prevalence of fasciolosis in the wet season could be attributed to the activities of the snail intermediate hosts. It has been described that the breeding requirements of the *Lymnaea* snails reach the optimum threshold during the wet months of the year [27]. Abraham and Jude [20] noted that the seasonal prevalence of fascioliasis favoured raining season when most pastures were green and grazing was with little difficulties. Ejeh et al. [28] however reported the prevalence of fasciolosis in cattle in Makurdi abattoirs, Benue State, Nigeria, to be high during the dry season and onset of wet season and noted a strong association between the detection of *Fasciola* in cattle slaughtered in the study area and season.

The moderately low intensity observed in this study could be attributed to many factors among which may include better management of cattle in terms of their grazing site and the kind of water they drink. This implies that healthier cattle are

now being slaughtered in the Southern Nigerian market. Transportation of these cattle can also serve as a yardstick for these results, as the use of lorries and trailers to transport these cattle restrict them to the shepherds choice of pasture to graze on and reduces the rigors of migration [22,16].

Fifty Eight (90.6%) cattle had light infections. This is different from the findings of Ekwunife and Eneanya [22] which recorded that out of the 166 diseased liver reported, 26(15.7%) had light worm load, 77(46.4%) had medium worm load and 63(38%) had high worm load of *Fasciola gigantica*. In the present study, the lowest number of worms per liver was one and the highest was 100. This is also similar to the findings of Ekwunife and Eneanya [22]. They recorded the lowest number of worms per liver as three and the highest as 88.

Pathological lesions caused by bovine fascioliasis are the major cause of liver condemnation [28]. The economic loss as a result of condemnation of liver during this study was estimated at ₦ 256,000 accruing from a total of 320kg of condemned livers. The highest financial loss (₦ 80,000) was recorded in the month of July and the lowest (₦ 56,000) in the month of April. This is higher than the findings of Usip et al., [16], who recorded an economic loss of ₦ 136,800 due to fascioliasis, but is similar to findings of Akpabio [18], who reported a total economic loss of ₦ 269,295 accruing from a total of 356.2kg of liver. Usip et al., [16] reported the highest financial loss in September (₦ 79,200) and the lowest in February (₦ 23,650). The result of this study is lower than that reported by Danbirni et al., [12] in Kano State, Nigeria. It was reported that the sum of ₦ 354,960 was lost from condemned liver (295.8 kg) due to fascioliasis.

Gross pathological changes were observed in the infected livers examined. These include enlargement and haemorrhage on the parietal surface of the liver, and this condition is partly due to the inflammatory changes and fibrosis that took place in the liver parenchyma. The affected bile ducts were observed to be thickened with fibrosis on the duct wall. Damaged hepatic parenchyma resulting in severe haemorrhage, thickening and gross fibrosis of bile duct were responses to the migrating flukes [29,20].

The present study showed infiltration of mononuclear inflammatory cells in proliferated fibrous tissue among hyperplastic newly formed

bile ductules. Similar results have been observed by Salmo et al., [29] and Okoye et al., [30] in cattle. Trivilin et al., [31] also observed that the liver lesions more prevalent were biliary duct proliferation, mononuclear cell infiltration, arteriosclerosis and periportal and periductal fibrosis.

The present study also revealed necrosis of hepatocyte and dislodgement of hepatic cells at some point. This observation agrees with findings of Abraham and Jude [20] and Okoye et al. [30]. The present study revealed the presence of degenerating immature flukes in some livers, embedded within the necrotic and fibrotic tissues. These could be flukes destroyed by the granulocytes. This is similar to findings reported by Haroun et al. [32], who observed that degenerative and necrotic changes in hepatocytes are associated with haemorrhage, fibrosis as well as mononuclear cell infiltration with haemosiderin deposition in fluke tracks.

The present study also revealed the presence of a central vein and accumulation of debris with these being indicators of obstruction of liver functions, including protein synthesis. This trend was also observed by Abraham and Jude [20]. In the present study, glandular hyperplasia of the bile ducts was observed. This is mainly seen in bile ducts containing many adult flukes. Okoye et al., [30] similarly reported that the presence of mature flukes within the lumen of the intra-hepatic bile ducts bring about continuous irritation, leading to hyperplastic proliferations. This damage is supposedly caused by the spiny surface of the flukes as well as their feeding habits on the hyperplastic bile ducts.

5. CONCLUSION

Fascioliasis has been shown to be of serious economic importance to the livestock industry in Nigeria where most livestock farmers, slaughter houses as well as traders are still ignorant of this disease. The intensity of fascioliasis in cattle greatly affects the histology of the liver. Although the prevalence and/or intensity of infection is moderately low in cattle slaughtered in Ikot Eneabong Abattoir, Calabar, Cross River State, the economic implication as well as the health implication should not be overlooked.

COMPETING INTERESTS

Authors have declared that no competing interests exist.

REFERENCES

1. Odigie EB, Odigie JO. Fascioliasis in Cattle: A survey of abattoirs in Egor, Ikpoba-Okha and Oredo Local Government Areas of Edo State using histochemical techniques. Intl J Basic ApplInno Research. 2013;(1):1-9.
2. Okoli IC, Agoh EC, Okoli GC, Idemili GC, Umesiobi DO. Bovine and caprine fascioliasis in Enugu State, Nigeria: Retrospective analysis of abattoir records (1993-1997) and six months prevalence study. Bull Anim Health Prod Afr. 2000;48: 7-11.
3. Hillyer GV. *Fasciola* antigens as vaccines against fascioliasis and schistosomiasis. J Helminthol. 2005;79(3):241-247.
4. Eze NC, Briggs AA. Prevalence of fascioliasis and histopathology of the liver in Cattle slaughtered in Port Harcourt abattoir, Rivers State Nigeria. World News Nat Sci. 2018;16:105-106.
5. Chick BF, Geering WA, Roe RT, Chapman L. Economic significance of *Fasciola hepatica* infestation of beef cattle – A definition study based on field trial and grazier questionnaire. 2nd International Symposium. Vet Epidemiol Economic Proceedings. 1980;377-382.
6. Ibironke AA. A retrospective study of liver fluke disease in Cattle based on abattoir data in Agege, Lagos, Nigeria. Afr J Food Agric Nutrition Dev. 2010;10:2.
7. Njoku-Tony RF. Bovine fascioliasis among slaughtered Cattle in selected abattoirs in Imo State, Nigeria. World Rural Observ. 2011;3(1):59-63.
8. Tolosa T, Tigre W. The prevalence and economic significance of bovine fasciolosis at Jimma Abattoir, Ethiopia. Int J Vet Med. 2006;3(2):1-7.
9. Petros A, Kebede A, Wolde A. Prevalence and economic significance of bovine fasciolosis in Nekemte Municipal abattoir. J Vet Med Animal Health. 2013;5(8):202-205.
10. Ali TS, Zarichehr V, Reza TM, Amroallah B, Hossin T, Amir M, et al. Prevalence of liver flukes infections in slaughtered animals in Kashan Isfahan province, central Iran. IIOAB J. 2011;2(5):14-18.
11. Chen JX, Chen MX, Xu XN, Jiav JM. An outbreak of human *Fasciola gigantica* in South West China. PLoS One. 2013;8(8): 9.
12. Danbirni S, Ziyauhaq H, Allam L, Okayeto SO, Sackey AKB. Prevalence of liver condemnation due to fascioliasis in slaughtered cattle and its financial losses at Kano Old abattoir. Nig J Vet Adv. 2015; 5(6):1004-1009.
13. Joan N, Stephen MJ, Bashir M, Kiguli J, Orikiriza P, Bazira J, et al. Prevalence and economic impact of bovine fasciolosis at Kampala City abattoir, Central Uganda. Brit Microbiol Res J. 2015;7(3):109-117.
14. National Population Commission. Nigeria population census Report. 2006;62–65.
15. Soulsby EJ. Helminths, arthropods and protozoa of domesticated animals. Bailliere, Tinda and Cassel, London. 1982;300.
16. Usip LP, Ibang ES, Edoho HJ, Amadi EC, Utah E. Prevalence of fascioliasis and the economic loss of condemned liver due to *Fasciola* infection in Cattle slaughtered at three abattoirs in Eket Urban, Akwa Ibom State of Nigeria. Global Adv Res J Food Sci Tech. 2014;3(2):54-75.
17. Bancroft JD, Marilyn G. Theory and practice of histological techniques. 5th Edition. London Press. 2002;256.
18. Akpabio U. Incidence of bovine fasciolosis and its economic implications at Trans Amadi abattoir, Port Harcourt, Nigeria. Acta Parasitol Globalis. 2014;5(3):206-209.
19. Ogunrinade A, Ogunrinade BI. Economic importance of bovine fasciolosis in Nigeria. Trop Anim Health. 1980;12:155-160. Available:<https://doi.org/10.1007/BF02242647>
20. Abraham JT, Jude IB. Fascioliasis in Cattle and Goat slaughtered at Calabar abattoirs. J Bio Agric Health Care. 2014;4(18):34-40.
21. Ayelign M, Alemneh T. Study on prevalence and economic importance of bovine fasciolosis in three districts of North-East Amhara Region, Ethiopia. J. Infect Non Infect Dis. 2017;3:024.
22. Ekwunife CA, Eneanya CI. *Fasciola gigantica* in Onitsha and environs. Animal Res Intl. 2006;3(2):448-450.
23. Ozung PO, Owai PU, Oni KO. An assessment of the prevalence of fascioliasis of ruminants in Ikom abattoir of Cross River State, Nigeria. Continental J Vet Sci. 2011;5(1):1-5.
24. Yahaya A, Tyay YB. A survey of gastrointestinal parasitic helminths of bovine slaughtered in abattoir, Wudil Local Government Area, Kano State, Nigeria.

- Greener J Biological Sci. 2014;4(4):128-134.
25. Ngele KK, Ibe E. Prevalence of fasciolopsis in cattle slaughtered at Eke Market abattoir, Afikpo, Ebonyi State, Nigeria. Anim Res Int. 2014;11(2):1958-1963.
26. Jaja IF, Mushonga B, Green E, Muchenje, V. Financial loss estimation of bovine fasciolosis in slaughtered cattle in South Africa. Parasite Epidemiol Control. 2017; 2(4):27-34.
27. Abebe W, Keffale M, Adugna S. Prevalence of bovine fasciolosis and its economic significance in Bonga Abattoir, Kafa Zone, Southwestern Ethiopia. Acta Parasitol Globalis. 2016;7(3):126-131. DOI: 10.5829/idosi.apg.2016.126.131
28. Ejeh EF, Paul BT, Lawan FA, Lawal JR, Ejeh SA, Hambali IU. Seasonal prevalence of bovine fascioliasis and its direct economic loss due to liver condemnation at Makurdi abattoirs, North Central Nigeria. Sokoto J Vet Sci. 2015;13(2):42-48.
29. Salmo NAM, Hassan SMA, Saeed AK. Histopathological study of chronic liver fascioliasis of cattle in Sulaimani abattoir. Al-Qadisiya J Vet Med Sci. 2014;13(2):71-80.
30. Okoye IC, Egbu FMI, Ubechukwu PO, Obiezue NR. Liver histopathology in bovine fascioliasis. Afri J Biotechnology. 2015;14(33):2576-2582.
31. Trivilin LO, Sousa DR, Nunes LC, Rocha NS, Martins IVF. Histopathology aspects and fibrosis evaluation of bovine naturally infected livers by *Fasciola hepatica*. Archives of Vet Sci. 2014;19(1):61-69.
32. Haroun EM, Gadir HA, Gameel AA. Studies on naturally occurring ovine fascioliasis in the Sudan. J Helminthol. 1986;60(1):47-53.

© 2020 Usang et al.; This is an Open Access article distributed under the terms of the Creative Commons Attribution License (<http://creativecommons.org/licenses/by/4.0>), which permits unrestricted use, distribution, and reproduction in any medium, provided the original work is properly cited.

Peer-review history:
The peer review history for this paper can be accessed here:
<http://www.sdiarticle4.com/review-history/57640>